

Endovascular treatment with onyx of vein of Galen aneurysmal malformation type II: Case report

Eugen Enesi¹, Arben Rroji¹, Fatmir Bilaj¹, Sonja Saraci (Butorac)¹, Iva Rudi¹, Mentor Petrela²

¹Department of Imaging, University Hospital Center “Mother Theresa”, Tirana, Albania;

²Department of Neurosurgery, University Hospital Center “Mother Theresa”, Tirana, Albania.

Corresponding author: Eugen Enesi, MD

Address: Rr. “Dibres”, No. 371, Tirana, Albania;

E-mail: eugenenesi@gmail.com

Abstract

Vein of Galen Aneurysmal Malformation (VGAM) constitutes a rare congenital brain vascular malformation, with different clinical presentations at different age groups according to the predominant type of the malformation.

Herewith, we report on a case of VGAM Type II presenting with increasing head circumference and hydrocephalus, treated with transarterial embolization using Onyx 18 (ev3 Neurovascular, Irvine, CA) with good long-term outcomes, both in the clinical and imaging aspect.

Due to the differences in VGAMs presentation, management of VGAMs has proved to be challenging, with intra-arterial embolization constituting the treatment of choice.

Our patient hospitalized at the University Hospital Center “Mother Teresa” in Tirana, Albania, responded well in terms of clinical and angiographic improvement to endovascular therapy with intra-arterial embolization using Onyx, an agent not widely used in the pediatric population and especially in patients with VGAM.

Keywords: aneurysmal malformation, case report, Vein of Galen.

Introduction

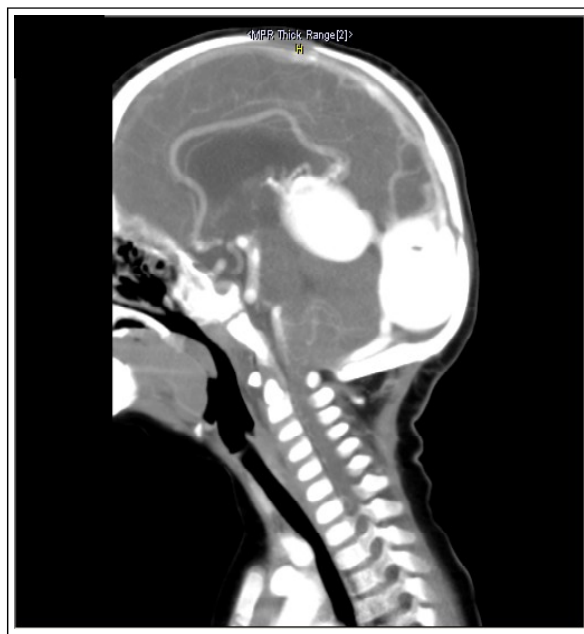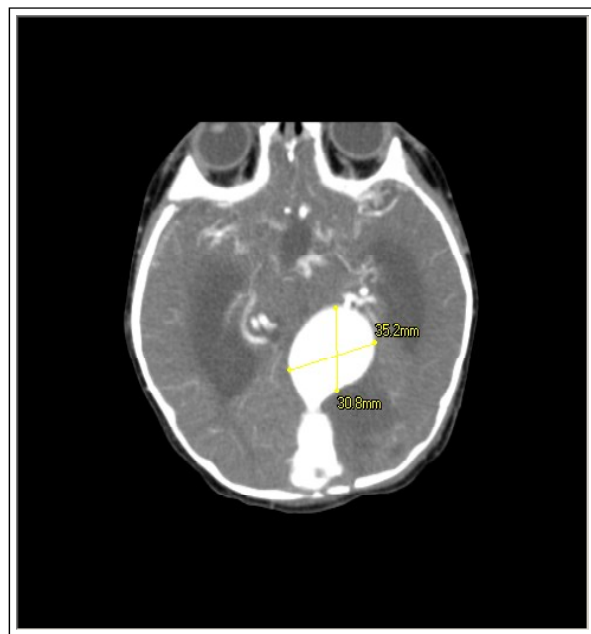Vein of Galen Aneurysmal Malformation (VGAM) constitutes a rare congenital brain vascular malformation, with different clinical presentations at different age groups according to the predominant type of the malformation. In addition to the differences in their presentation, the nature of these malformations, variability in evolution, angio-architecture, and the different effects on systemic physiology, make their management challenging. We introduce a case of VGAM Type II presenting with increasing head circumference and hydrocephalus, treated with transarterial embolization using Onyx 18 (ev3 Neurovascular, Irvine, CA) with good long-term outcomes, both in the clinical and imaging aspect.

Case Presentation

A 7-month old Albanian male was referred for CT-scan due to macrocrania and cyanosis on effort,

otherwise with a normal development. The infant did not have any neurological disorders and no signs of heart failure with Bicêtre score within normal ranges (1). The child had previously undergone fetal and transcranial ultrasound which had described a cystic lesion in the pineal region. Other examinations turned out to be normal. The CT angiography (CTA) revealed Vein of Galen (VGAM) Type II, dilatation measuring 3.5x3.1 cm in diameter, a few tortuous arterial feeders from both the anterior and posterior circulation and moderate obstructive triventricular hydrocephalus (Figure 1A, B). Due to the evident obstructive hydrocephalus with potential subsequent brain damage (possible future dystrophic or ischemic changes) and in order to avoid any potential future intracranial hemorrhage or cardiac failure, the patient was considered for trans-arterial embolization of the VGAM with Onyx.

Figure 1. A, B. Axial and sagittal CTA respectively, show VGAM in a 7-month male infant. Note the VGAM dilatation (black arrow), and a few arterial feeders (black arrowhead) along the border of the enlarged vein. Mild stenosis of the straight sinus with post-stenotic dilatation of its distal part and torcula is also evident; furthermore, associated obstructive triventricular hydrocephalus is observed

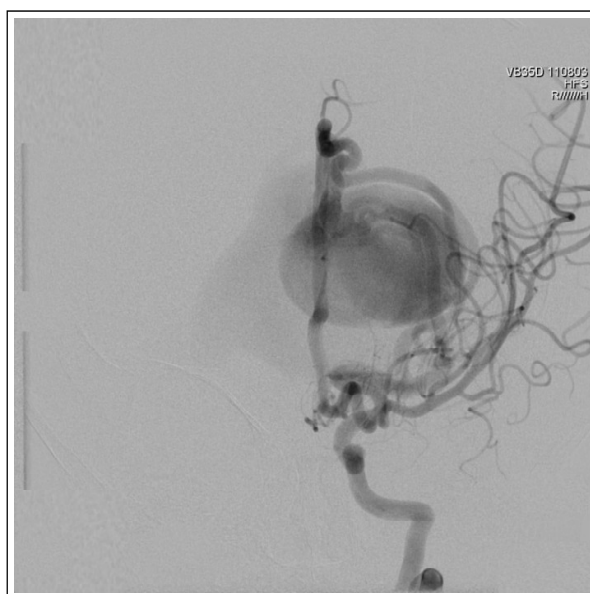
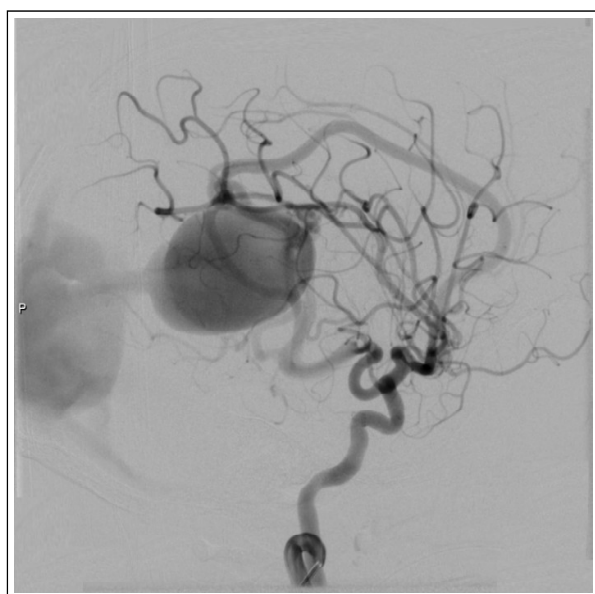

Under general anesthesia, a 4F catheter system was introduced in a transfemoral route for diagnostic angiography.

Angiograms (Figure 2 A, B) confirmed the findings of VGAM with arteriovenous shunt with arterial

feeders from both the posterior and anterior circulation, but without a complex arterial maze. At the same time, the patient underwent embolization of the VGAM with Onyx 18 (ev3 Neurovascular, Irvine, CA).

Figure 2. A, B. Pretreatment DSA – respectively, antero-posterior and lateral projections of the left Internal Carotid Artery (left ICA) angiogram (recorded as *ACI sin* on the image). VGAM is obvious with instantaneous venous filling due to the arteriovenous fistula with dilatation of the ‘vein of Galen’ (black arrow). Obvious pericallosal feeder distal to the dilated vein of Galen with a few other concomitant arterial feeders were noticed without a complex arterial maze (black arrowhead)

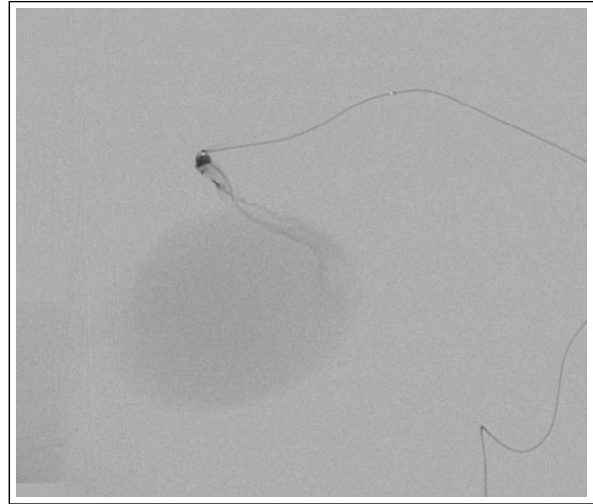
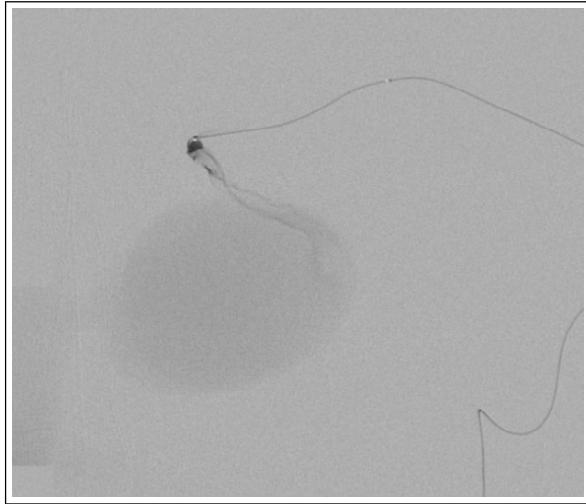


During the endovascular procedure (Figure 3A), the same catheter was used to guide a microcatheter for super-selective embolization distally to the anterior cerebral artery (ACA) close to the fistula. 1ml Onyx 18 was injected to definitely occlude the main arterial feeder into the fistula. A minimal amount of Onyx migrated up to the torcula during the procedure, but no sinus occlusion occurred and no territorial infarcts were observed during or

following the procedure. The microcatheter was successfully withdrawn, with no vessel dissection or hemorrhage.

The embolization results after treatment showed the presence of Onyx in the main arterial feeder (Figure 3B), slowing of the flow with concomitant partial occlusion of the VGAM; presence of residual reduced flow was due to the remaining arterial feeders.

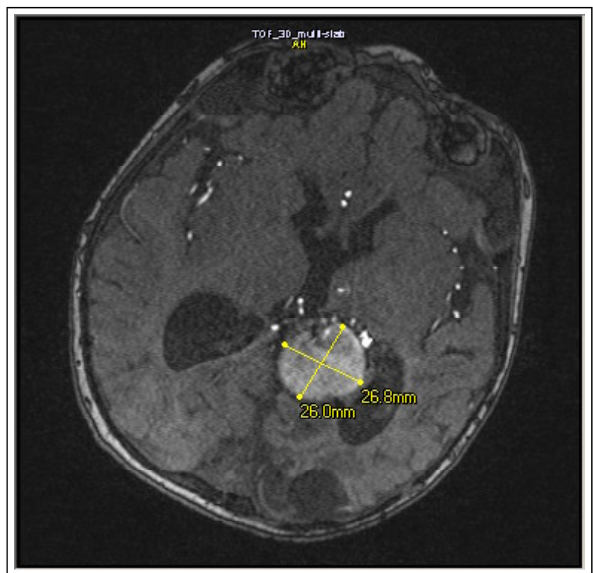
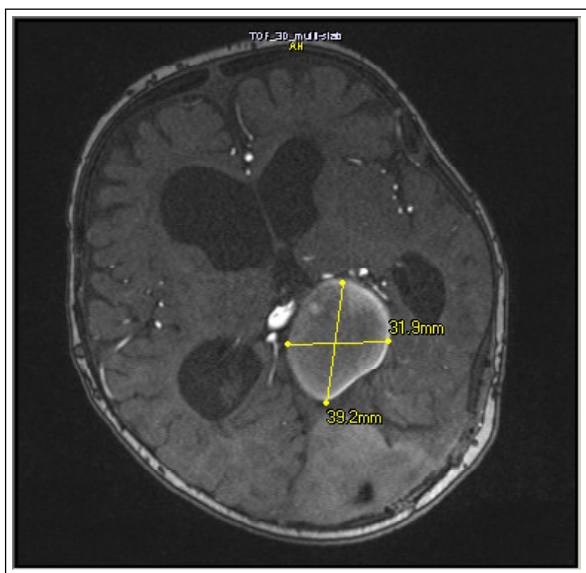
Figure 3. A, B. DSA obtained immediately before and after embolization. Fig. 3A – lateral projection shows microcatheter injection distal to the left anterior cerebral artery (ACA) close to the arteriovenous fistula with absence of nidus vessel configuration. Fig. 3B- lateral projection of the left ICA angiogram shows the presence of the embolization agent (black arrow) in the main arterial feeder vessel; besides was noticed slowing of the flow post-embolization. Note a small amount of migrated Onyx to the torcula (black arrowhead), whereas no sinus venous occlusion was observed



A total amount of 18 ml diluted contrast was used during the whole procedure to prevent contrast-induced nephrotoxicity. The hemodynamic and ventilatory parameters were carefully monitored and remained normal throughout the procedure.

The patient was clinically and neurologically intact after therapy. Post-procedure MRI (Figure 4A) showed continued but reduced flow into the dilated vein from several remaining arterial feeders with mild regression of the size of the malformation.

Figure 4 A, B. 3D TOF MRI – obtained immediately after the treatment and three months after the treatment, shows reduction in size of the VGAM up to 30% at three months post treatment, straight sinus was patent



The infant underwent close follow-up, further treatment was not performed due to the absence of signs and symptoms of morbidity and good response of hydrocephalus to treatment. Imaging 3-months post-treatment (Figure 4B) confirmed significant regression of the aneurysmal malformation (nearly 30%) at 3-months after treatment and good patency of the straight sinus (Figure 4B). We noticed that the reduction of hydrocephalus was associated with subsequent prevention of potential future dystrophic/ischemic brain changes. Moreover the infant shows a normal development after 1 year of therapy.

Discussion

VGAM constitutes a rare brain vascular malformation, accounting for less than 1% of cerebrovascular malformations with arteriovenous shunting (2,3). However, in the pediatric population, it is encountered in 30% of children with symptomatic brain vascular malformations (4,5). Essentially, VGAM is defined as a direct arteriovenous fistula between a variety of feeding arterial vessels - mainly the deep choroidal arteries - and a persistent embryonic precursor of the vein of Galen, the median prosencephalic vein of Markowski (MPV) (6,7).

The current most widely accepted classification is that of Lasjaunias and Yaşargil; the former widely used by endovascular interventionists and the latter as a more descriptive model, better applied in open neurosurgery (8,9). Lasjaunias described two groups of these malformations: (type I) the choroidal more severe and complex form; and (type II) the mural type manifesting later in infancy (8,9). The clinical picture of our patient was compatible with mural type VGAM, which was confirmed angiographically.

The clinical picture varies according to the age-group, neonatal VGAMs are more common than those presenting in infancy or childhood. Neonatal VGAMs usually manifest with high-output congestive heart failure and a loud cranial bruit

(4,10). Hydrocephalus results from abnormal hemodynamic conditions present at the confluence of sinuses, the posterior convergence of the venous drainage of the brain and the immaturity of the granulation system, besides aqueducts or posterior third ventricle compression (8). Our patient showed only a mild cyanosis on effort. The main presenting symptoms were increasing head circumference and hydrocephalus which were treated with endovascular treatment with gradual reduction of the hydrocephalus and the size of the malformation.

Treatment options are variable. Endovascular therapy with transarterial embolization is considered the treatment of choice, with the goal to achieve, as far as possible, a normal neurological development. The reported successful rate is high, with up to 74% of treated patients neurologically normal at long-term follow-up (9). Another treatment option, such as radiosurgery can be considered as complementary treatment in selected cases (5). While, surgical approach has played some role prior to the endovascular therapy, especially for types I-III lesions according to Yaşargil classification, surgical intervention is contraindicated to type IV malformations (11).

We emphasize that the ultimate goal of endovascular therapy is not the anatomic cure of VGAM, but rather the sufficient control of the malformation (30%-50% reduction in the neonate period) to allow normal brain maturation and development. Treatment eligibility in the neonatal period is determined by the Bicêtre neonatal evaluation score, which takes in consideration the cardiac, cerebral, respiratory, hepatic and renal function (4). In the infant age-group (from one month to one year of age), the immediate goal of treatment is to preserve the hydro-venous development and thus normal brain development, and to exclude the lesion. Hydrocephalus in these patients is mainly due to intracranial venous hypertension and frequently responds to treatment of the lesion.

Glue (n-BCA) has been the preferred agent of embolization due to its resistance to recanalization, but there are a growing number of reports showing good outcomes with the use of Onyx. Some of the main known advantages of Onyx vs. n-BCA glue lie in its chemical composition and that Onyx injections are much easier to control. There are only a few publications on the use of Onyx in the pediatric age-group (12,13-15). One of the largest groups, reported by Thiex et al. (3), showed encouraging outcomes of embolization with Onyx, in terms of clinical and angiographic improvement, with an extremely low rate of transient morbidity and permanent morbidity or mortality, thus proving to be an efficacious technique. Our patient was treated with transarterial embolization with up to 30% reduction of the VGAM 3-month post-procedure, he was neurologically intact and has shown normal development one year after the endovascular treatment.

Reported complications of embolizations include:

procedure-related death, risk of transient and/or permanent neurological disability, risk of hemorrhage and risk of neurological complication. Vessel perforation, dissection, unintended occlusion or stuck catheters are other possible complications related to embolization with Onyx. Even though there was a mild migration of onyx up to the torcula, no sinus venous occlusion was noticed, besides no complications occurred throughout the endovascular procedure and post-procedure in our patient.

Due to the differences in VGAMs presentation, management of VGAMs has proved to be challenging, with intra-arterial embolization constituting the treatment of choice. We emphasize that our Albanian patient responded well – in terms of clinical and angiographic improvement – to endovascular therapy with intra-arterial embolization using Onyx, an agent not widely used in the pediatric population and especially in patients with VGAM.

Conflicts of interest: None declared.

References

1. Lasjaunias P. Vascular Diseases in Neonates, Infants and Children: Interventional Neuroradiology Management. Berlin: Springer; 1997:49.
2. Mortazavi MM, Griessenauer CJ, Foreman P, Bavarsad Shahripour R, Shoja MM, Rozzelle CJ, et al. Vein of Galen aneurysmal malformations: critical analysis of the literature with proposal of a new classification system: A review. *J Neurosurg Pediatr* 2013;12:293-306.
3. Thiex R, Williams A, Smith E, Scott RM, Orbach DB. The Use of Onyx for Embolization of Central Nervous System Arteriovenous Lesions in Pediatric Patients. *AJNR Am J Neuroradiol* 2010;31:112-20.
4. Lasjaunias PL, Chng SM, Sachet M, Alvarez H, Rodesch G, Garcia-Monaco R. The management of vein of Galen aneurysmal malformations. *Neurosurgery* 2006;59:S184-94.
5. Payne BR, Prasad D, Steiner M, Bunge H, Steiner L. Gamma surgery for vein of Galen malformations. *J Neurosurg* 2000;93:229-36.
6. Jaeger JR, Forbes RP, Dandy WE. Bilateral congenital cerebral arteriovenous communication aneurysm. *Trans Am Neurol Assoc* 1937;63:173-6.
7. Markowski J. Entwicklung der Sinus duraematis und der Hirnvenen des Menschen. *Bulletin International de l'Académie des Sciences et des Lettres. Classe des Sciences Mathématiques et Naturelles. Serie B: Sciences Naturelles*; 1921.
8. Lasjaunias P, Ter Brugge KG, Berenstein A. Vein of Galen aneurysmal malformation, in: *Surgical Neuroangiography 3. Clinical and Interventional Aspects in Children*, ed 2. Berlin: Springer, Vol. 3, 2006:105-226.
9. Berenstein A, Fifi JT, Niimi Y, Presti S, Ortiz R, Ghatan S, et al. Vein of Galen malformations in neonates: new management paradigms for improving outcomes. *Neurosurgery* 2012;70:1207-14.
10. Chevret L, Durand P, Alvarez H, Lambert V, Caeymax L, Rodesch G, et al. Severe cardiac failure in newborns with VGAM. *Intensive Care Med* 2002;28:1126-30.

11. Yaşargil MG(ed). AVM of vein of Galen region, in: Microneurosurgery, Vol. IIIB: AVM of the Brain, Clinical Considerations, General and Special Operative Techniques, Surgical Results, Nonoperated Cases, Cavernous and Venous Angiomas, Neuroanesthesia. Stuttgart: Georg Thieme, 1988:323-54.
12. Weber W, Kis B, Siekmann R, Jans P, Laumer R, Kühne D. Preoperative embolization of intracranial arteriovenous malformations with Onyx. *Neurosurgery* 2007;61:244-52.
13. Jankowitz BT, Vora N, Jovin T, Horowitz M. Treatment of pediatric intracranial vascular malformations using Onyx-18. *J Neurosurg Pediatr* 2008;2:171-6.
14. Germanwala AV, Vora NA, Thomas AJ, Jovin T, Gologorsky Y, Horowitz MB. Ethylenevinylalcohol copolymer (Onyx-18) used in endovascular treatment of vein of Galen malformation. *Childs Nerv Syst* 2008;24:135-8.
15. Albuquerque FC, Ducruet AF, Crowley RW, Bristol RE, Ahmed A, McDougall CG. Transvenous to arterial Onyx embolization. *J Neurointerv Surg* 2014;6:281-5.